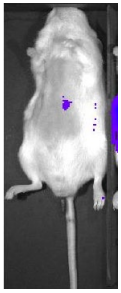


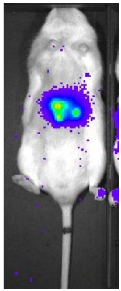
Ultrasound-guided intrahepatic injection for liver cancer model

Mahlavu-1

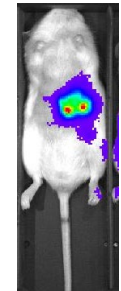
D6



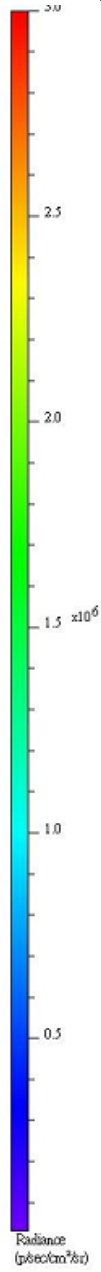
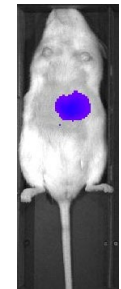
D14



D21

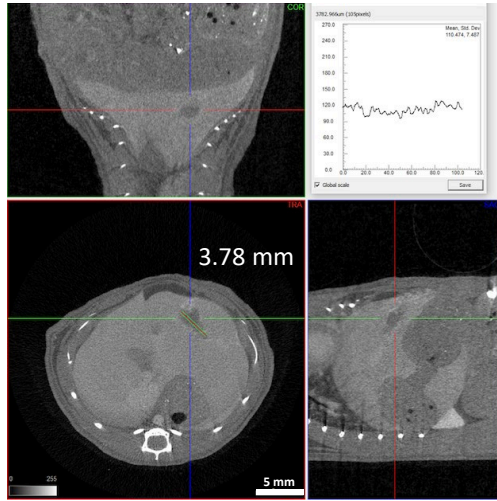


D28

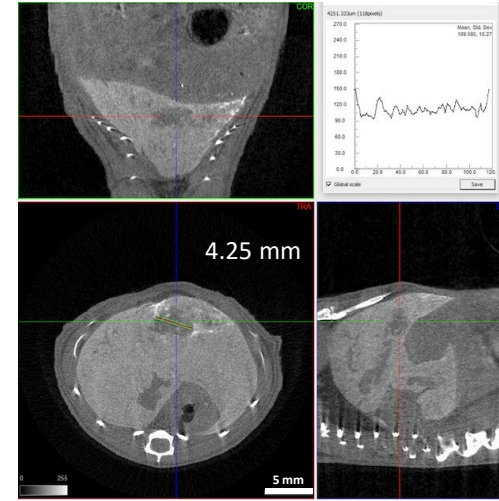


Min: 3e4
Max: 3e6

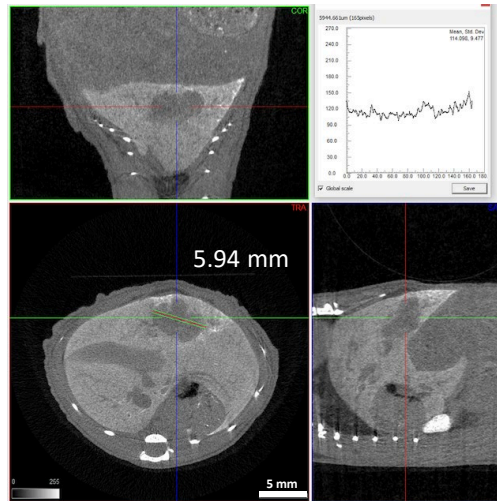
Exitron Nano 12000, 100 μ l tail vein injection @ Day 6



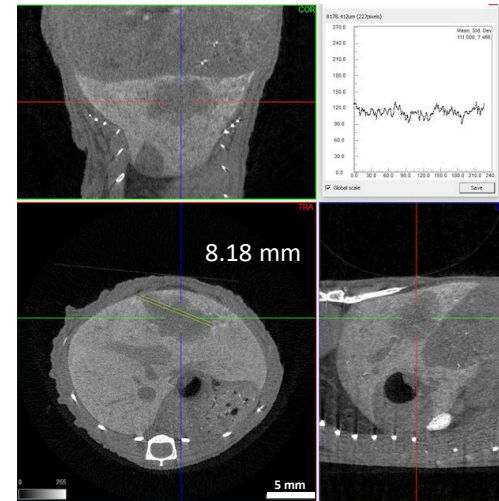
Day 6



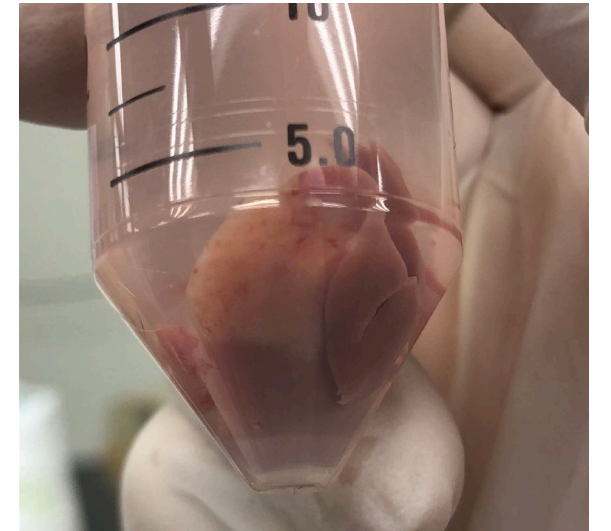
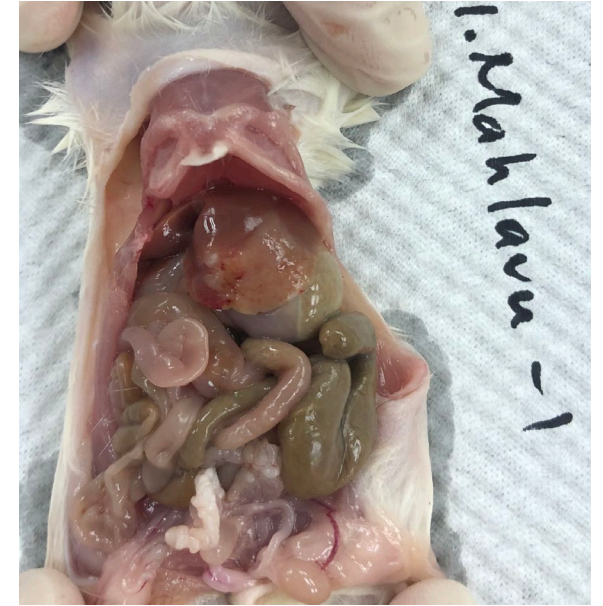Day 14

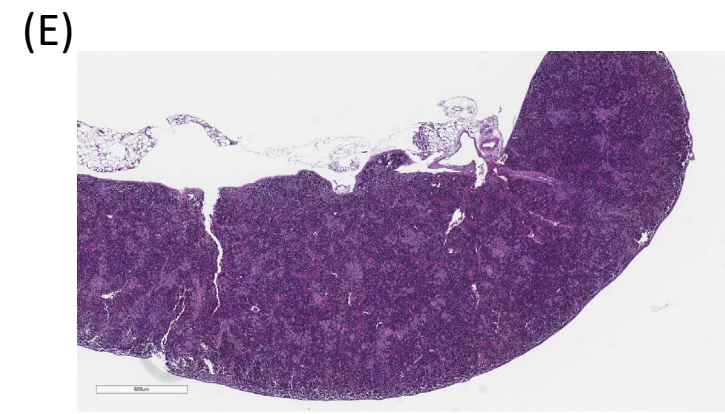
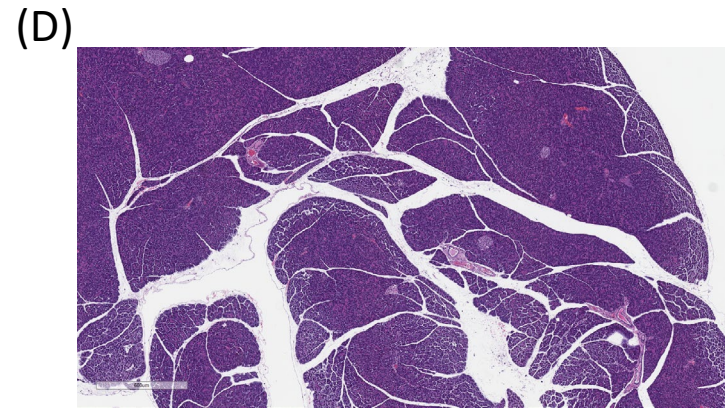
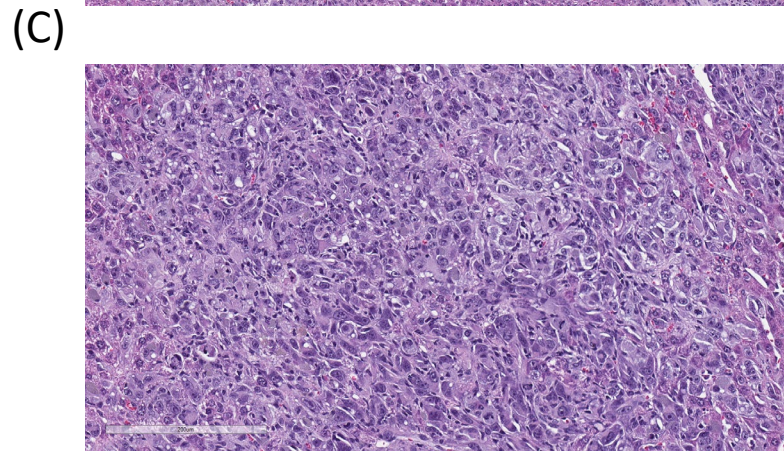
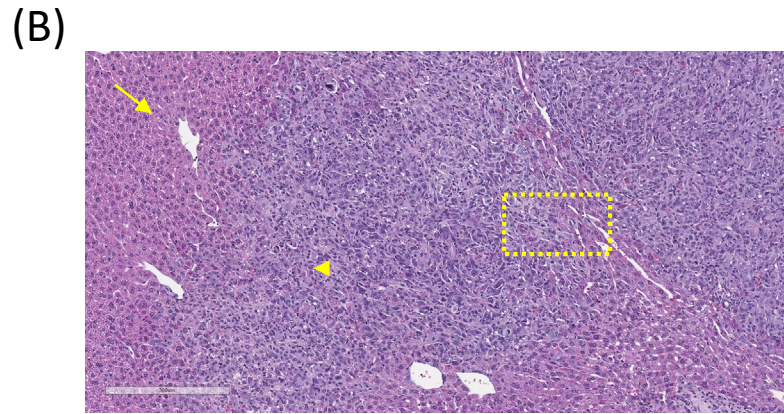
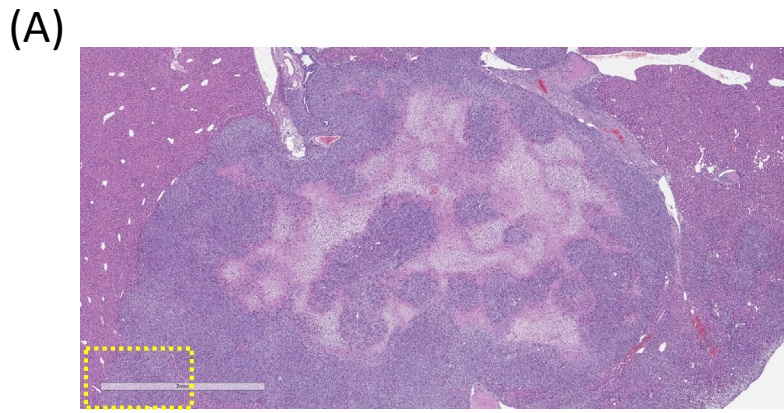


Day 21



Day 28





- (A) Liver section, 2X. Non-capsulated demarcate multifocal neoplastic nodules with central necrosis were shown in the low power field.
- (B) Liver section, 10X. Neoplasm with fairly margin was shown. Arrow, hepatocyte; Arrowhead, neoplasm.
- (C) Liver section, 40X. Neoplasm with slightly spindle differentiation and multinucleated neoplastic cells were noted.
- (D) Pancreas section, 4X. No significant finding was noted.
- (E) Spleen section, 4X. No significant finding was noted.