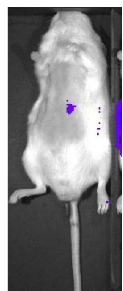


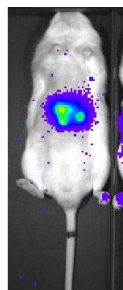
Mahlavu-1

超音波導引肝內注射腫瘤細胞建立小鼠的肝癌模型

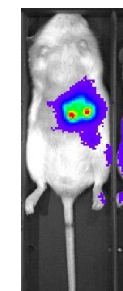
D6




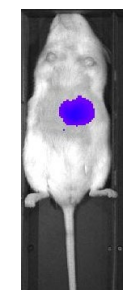
D14



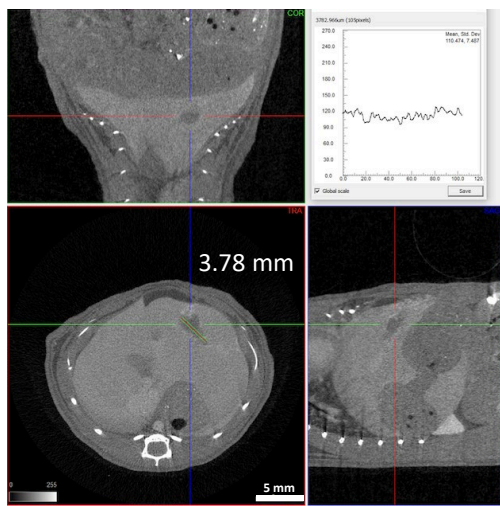
D21



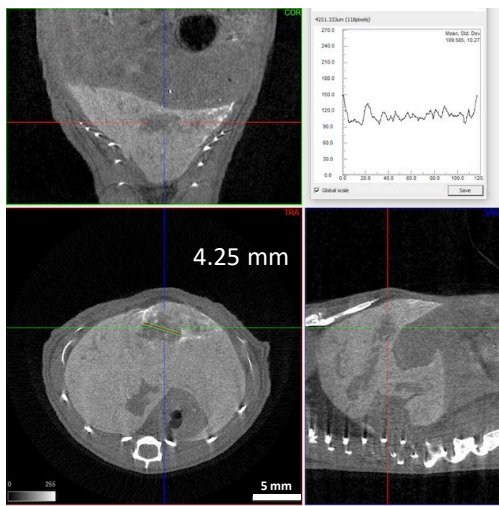
D28



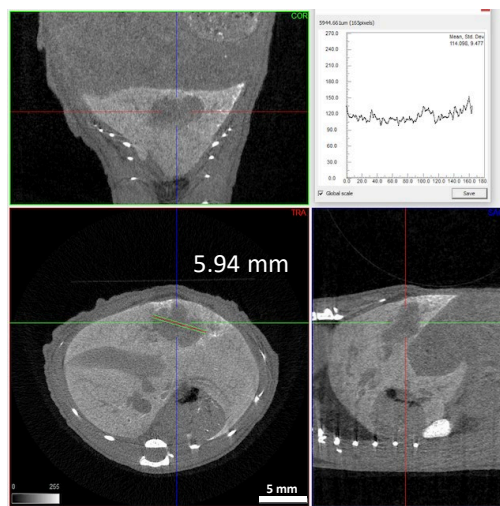
Exitron Nano 12000, 100μl tail vein injection @ Day 6



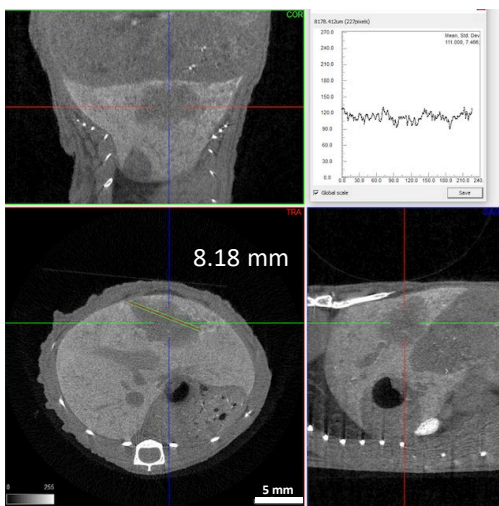
Day 6



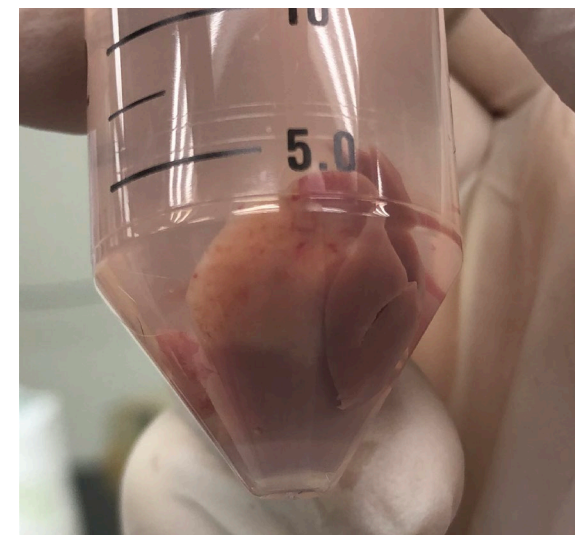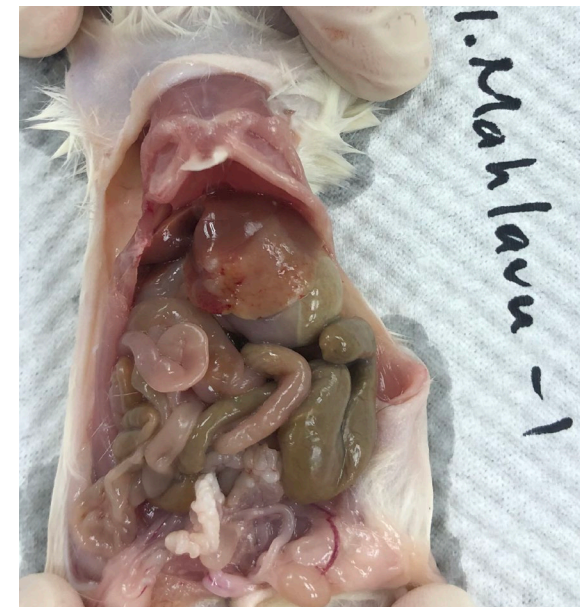Day 14

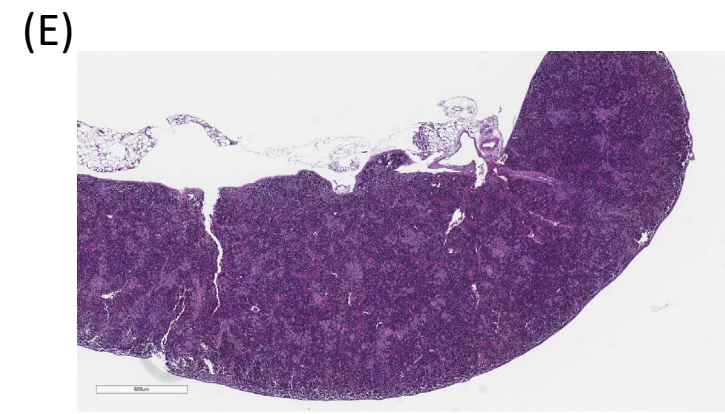
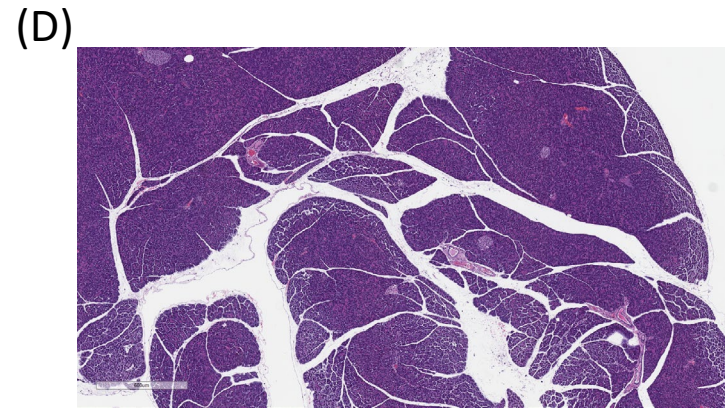
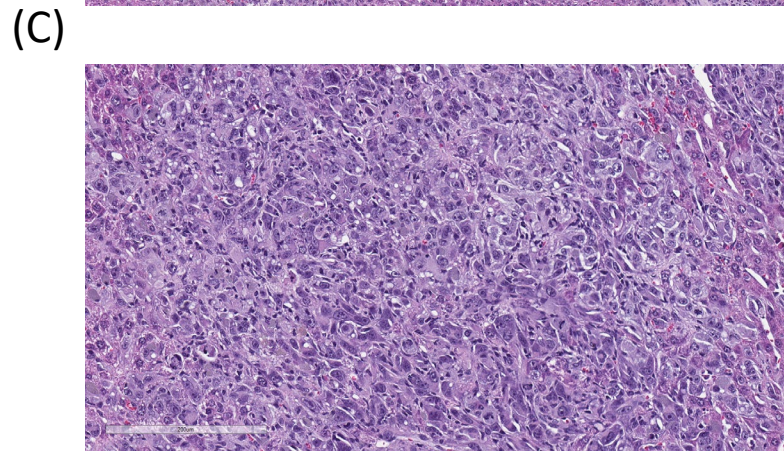
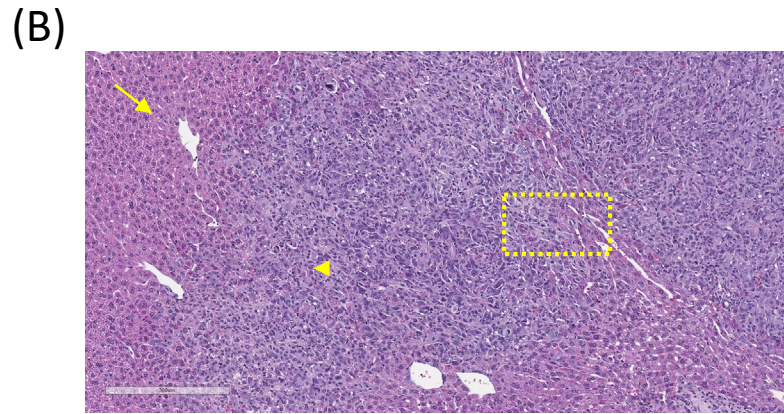
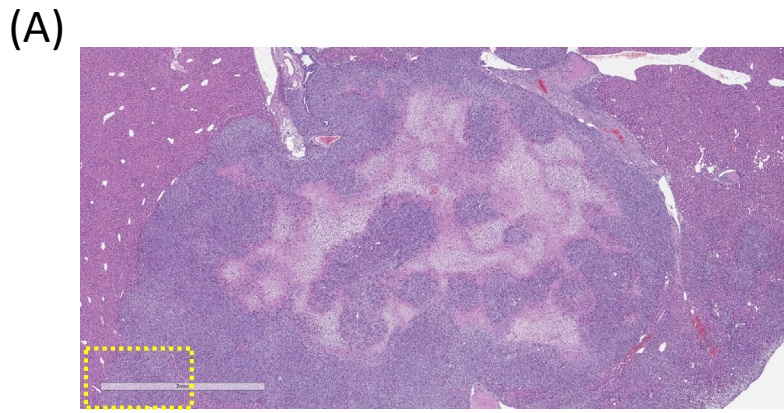


Day 21



Day 28





- (A) Liver section, 2X. Non-capsulated demarcate multifocal neoplastic nodules with central necrosis were shown in the low power field.
- (B) Liver section, 10X. Neoplasm with fairly margin was shown. Arrow, hepatocyte; Arrowhead, neoplasm.
- (C) Liver section, 40X. Neoplasm with slightly spindle differentiation and multinucleated neoplastic cells were noted.
- (D) Pancreas section, 4X. No significant finding was noted.
- (E) Spleen section, 4X. No significant finding was noted.